

Use of Autologous Mesenchymal Stem Cells in Treatment of Avascular Necrosis of the Hip- Technical Report and Results of a Case Study.

Gauresh Palekar¹

INTRODUCTION:

Avascular Necrosis (AVN) of the femoral head is a complex and poorly understood disease. The pathogenesis involves both a biological and a mechanical problem. The biological aspect of the disease is represented by the cellular death due to the initial insult of the injury followed by the inadequate and incomplete repair process of revascularization which leads to eventual collapse of the femoral head. Various pathophysiological mechanisms have been implicated in causing the initial insult of ischemia. However none can explain the deficient repair mechanisms in AVN which are responsible for eventual collapse of the femoral head. The inadequacy of the repair processes have been thought to be due to the pathological process of AVN causing disruption at the cellular level. The mechanical problem in AVN is represented by the subchondral fracture, which causes joint irregularity culminating in arthritis of the hip joint.

THE CELLULAR BASIS OF AVN:

Several authors have found abnormalities in the cellular elements in the bone marrow of patients suffering from AVN. Wienstien¹ demonstrated that patients having glucocorticoid induced AVN have an abnormal cellular population in bone marrow. He showed that glucocorticoids caused inhibition of osteoblastogenesis and promoted apoptosis of osteoblasts and osteocytes. Similarly Herginou² showed a decrease in the mesenchymal stem cell pool resulting in lower Fibroblast Colony Forming Units which are the progenitor cells of osteocytes. Gangji³ showed inadequate and abnormal osteoblastic cells in Trochanteric region of AVN patients which shows that this abnormal cellular population may be more widespread at areas other than the affected area. This was corroborated by O' Brian's⁴ who attributed the incomplete and inadequate repair after the avascular event to the decreased bone turnover due to osteoblastic dysfunction. Osteoblasts are the only bone forming cells in the body. They secrete a variety of angiogenic and osteogenic factors like Cytokines, angiogenic growth factors, fibroblast growth factor and Bone Morphogenic Proteins (BMP)-2/7 like proteins. They also influence the recruitment of Mesenchymal Stem

Cells and their transformation into osteoprogenitor cells.⁵

SUBCHONDRAL COLLAPSE IN AVN:

Loss of mechanical support of the subchondral bone to the cartilage is the reason for collapse in AVN. This leads to a stress riser resulting in further collapse of cartilage on weight bearing. If this depression of cartilage is more than 2 mm then the progression to arthritis is inevitable. The aim of joint preserving surgery is to restore the depression in cartilage to under 2mm by elevating the depression and to support it till the subchondral bone is strong to take the weight of the body.

Different approach was taken to tackle these two basic issues. The biological problem was corrected by use of autologous cultured Osteoblasts and mechanical problem by the elevation of the depressed cartilage and support by hydroxapatite.

Autologous cultured Osteoblasts are a product of the researches of cellular medicine. In this procedure a few thousand of the patients' mesenchymal stem cells (MSC) are harvested from the bone marrow. Mesenchymal Stem cells are specialized cells present in the bone marrow of adults which have a capacity to replace a terminally differentiated cell derived from the mesenchyme with an identical cell.⁶ The stem cells are harvested, cultured, multiplied and finally differentiated into adult mature Osteoblasts. These Osteoblasts at the time of implantation number around 50 million. These autologous cells behave like Osteoblastic cells and produce various osteogenic and angiogenic cytokines which are responsible for improving the vascularity of the femur head. The dead bone is curetted out and is replaced with calcium hydroxapatite bone graft substitute. The advantage of Bone graft substitute over bone graft is that the substitutes are resorbed slowly and by changing the constituents of the graft it is possible to delay the resorption of the graft. The graft substitute used in this case (Hydroxapatite) has a special property of delayed absorption over 1 year. Use of hydroxapatite is well known in weight bearing regions in trauma surgery. Hydroxapatite is also not prone to collapse unlike autogenous bone graft which has to be resorbed before it gets replaced by new bone. With these two principles as our base we treated a case of young adult with AVN right hip with decompression, curettage and filling the void with a mixture of hydroxapatite and Autologous cultured osteoblasts.

Case: 24 yr old male presented with pain in right hip of 4 weeks duration and clunking noise from the hip.

¹Saifee Hospital and Bhatia Hospital, Mumbai, India

Address of Correspondence: Dr Gauresh Palekar,
Ganesh Bhuvan ,2nd bhatwadi Girgaum Mumbai 400004
Email: drgauresh@hotmail.com

Investigations and history revealed that he had bilateral Idiopathic Avascular necrosis of femoral head. At presentation on the right side he was Stage II B Ficat and Arlet ^{7,8} and Stage III in ARCO classification⁹ with a Superolateral Lesion, involving more than 60 % of femoral head, 2 mm depression of femoral cartilage (Fig 1). This stage of lesion has been shown to have a very high chance of progression to collapse and arthritis. On his left side was Stage I on Ficat and Arlet and Stage I ARCO There was high chance of progression as the lesion was Superolateral location and Large (more than 60%) however without a subchondral fracture but was asymptomatic at this stage.

Patient was offered a core decompression on his left side and a surgery with autologous cultured Osteoblasts and Calcium Hydroxapatite on his right side. The right hip joint was approached through a transverse anterior incision through a modified smith Peterson approach (Fig 2a). The longitudinal plane between the Sartorius and gluteus medius in the superficial plane and between the rectus femoris and gluteus medius in deeper plane was used to reach the hip joint. The reflected head of the rectus femoris was elevated off to expose the anterior hip joint capsule (Fig 2b). A transverse H

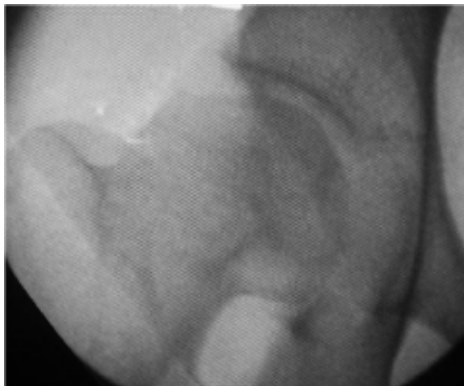

Figure 1: Radiograph of the right hip of the patient with stage IIb avascular necrosis of the femur.

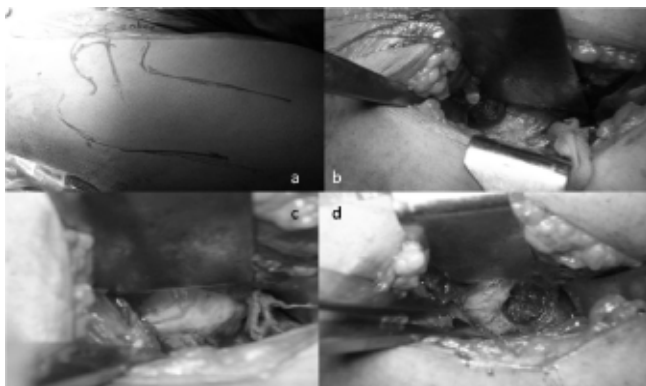


Figure 2: a- The skin marking for the modified smith Peterson. b- capsule exposed. C- capsule was incised to expose the bone cartilage kuction at the base of the head. d- a bone window was made in anterior cartilage bone junction measuring around 1cm diameter in the center of the neck avoiding the superior and inferior cortices.

capsulotomy was done of the anterior hip joint with the horizontal limb of the H along the axis of the femoral neck. The cartilage bone junction was identified (Fig 2c) and the hip examined under C arm till the flattened joint surface was identified on image intensifier. A round window was made in anterior cartilage bone junction measuring around 1cm diameter in the center of the neck avoiding the superior and inferior cortices (Fig 2d). All loose bone sequestrum was curetted out (Fig 3) and the cartilage was elevated inside out against the intact acetabular template (Fig 3b.c). Multiple drill holes were then made in the avascular area of the femoral head and were injected with the autologous cultured cells (Fig 3d). Finally the defect was filled with calcium hydroxapatite (Not Calcium Phosphate- which gets absorbed quickly) cement. The joint capsule was closed over a drain.

Postoperative protocol: Straight leg raising was started on second post operative day with active assisted and passive exercises till full range at hip was attained. Patient was kept

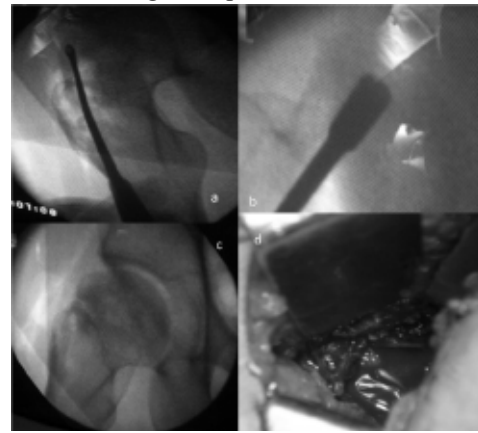


Figure 3: a- loose bone sequestrum was curetted out. b- The cartilage was elevated inside out against the intact acetabular template. c- Appearance of the head margins after elevation. d-the injected autologous cultured cell mixture that solidifies in a minute and seals with bone window too.

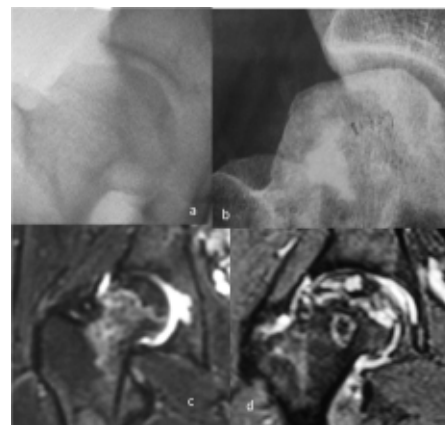


Figure 4- Comparison between preoperative (A) and 3 months post surgery Radiographs (b) with no progress in the lesion. The opacity due to calcium hydroxapatite can still be seen. C-preoperative MRI showing avascularity. d- 6 months postoperative MRI showing revascularisation

non weight bearing for 6 weeks after which toe touch weight bearing to partial weight bearing was started followed by full weight bearing by 3 months post surgery strengthening of the muscles surrounding hip joint can be done with four point exercise, isometric exercise, hamstring exercise and squatting exercise Patient was advised to avoid contact sports till 6 months.

FOLLOW UP

The patient was followed up over a period of 6 months and following changes were noted; No further progression of collapse, asymptomatic right side with full range of motion. The Opposite hip on which core decompression was done however progressed inspite of the core decompression to Stage III in 6 months. MRI done at 6 months showed significant revascularization in Autologous cell side as compared to Core decompressed side (Fig. 4)

Summary: Dual Pronged treatment of AVN hip with use of biological stimulators (autologous osteoblasts) and mechanical support (Hydroxapatite) may be an acceptable option in stage III AVN hip and may help in preserving the hip contour and prevent further collapse. A longer follow up with a large sample will be required to establish our hypothesis.

REFERENCES:

1. Weinstiens RS, Nicholos RW, Manolagas SC. Apoptosis of osteocytes in glucocorticoid induced Osteonecrosis of Hip. *J Clin Endocrinol Metab* 2000; 85: 2907-12
2. Herginou P, Beaujean F, Lambotte JC. Decrease in mesenchymal stem cell pool in corticosteroid induced osteoporosis. *JBJS Br* 1999 ; 81: 349-55
3. Gangji V, Hauzeur JP, Schoutens A. Abnormalities in replicative capacities of osteoblastic cells in proximal femur of patients with Osteonecrosis of femoral head. *J rheumatol* 2003 ; 30: 348-51
4. O' Brien CA, Jia D, Plotkin LI. Glucocorticoids act directly on Osteoblasts and osteocytes to induce their apoptosis and reduce bone formation and strength. *Endocrinology* 2004 ; 145 : 1835-41.
5. Hauge EM, Qvesel D, Eriksen EF. Cancellous bone remodeling occurs in specialized compartments lined by cells expressing osteoblastic markers. *J bone mineral res* 2001; 16:1575-82.
6. Muschler GF, Boehm C, Easley K. Aspiration to obtain human osteoblast progenitor cells from human bone marrow. *JBJS am* 1997; 79: 1699-709.
7. Ficat RP. Idiopathic bone necrosis of femoral head. : early diagnosis and treatment. *JBJS Br* 1985;67(1):3-9.
8. Ficat RP, Arlet J : Editor DS Hungerford. *Ischaemia and necrosis of bone* : Williams and Wilkinsons, 1980.
9. Gardeniers J. ARCO Committee on terminology and staging ARCO newsletter 1993:5: 79-82.

Source of Support: Nil, Conflict of Interest: none