

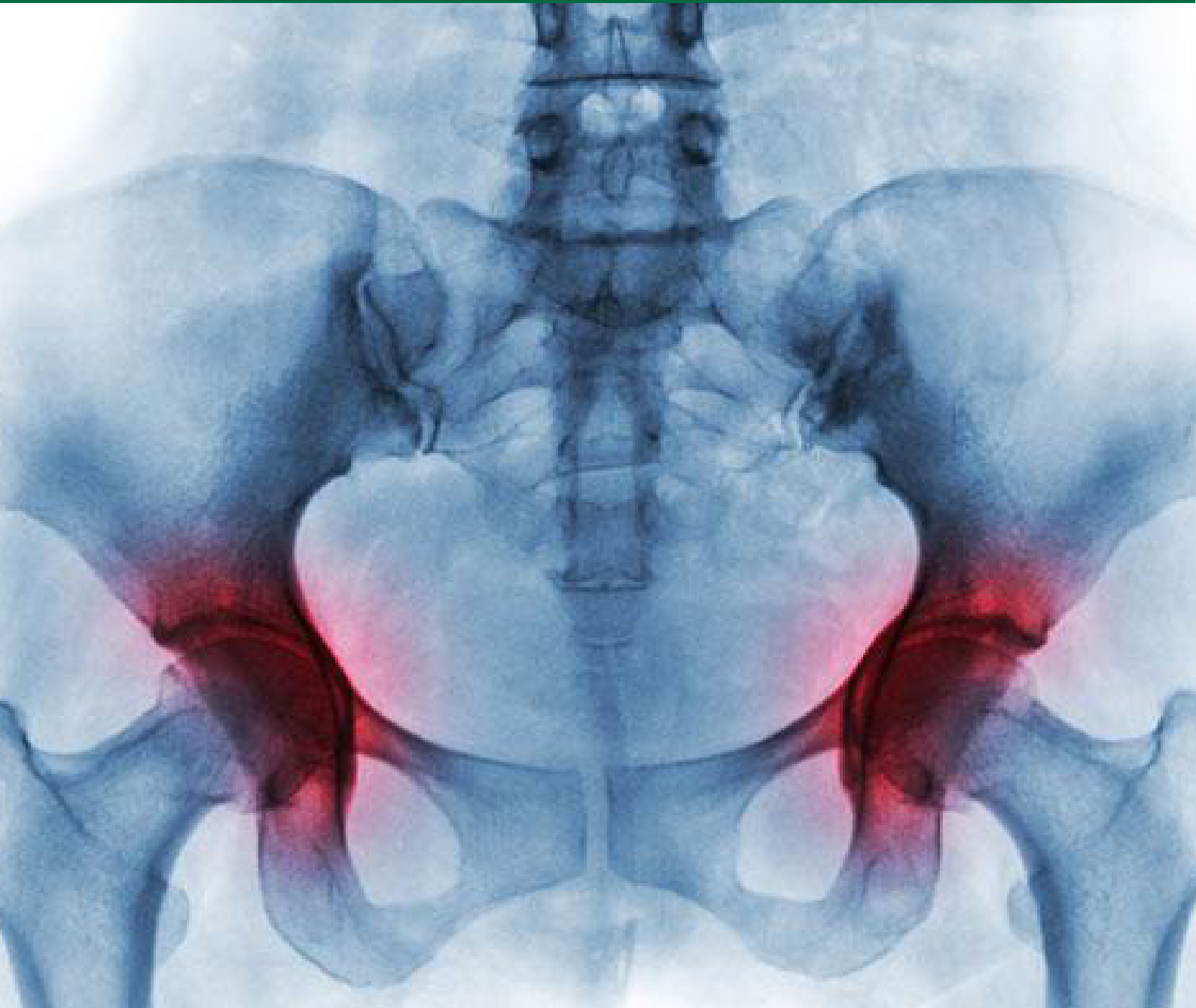
# ORTHOBIOLOGICS®

## Tackling Avascular Necrosis - The Silent Bone Killer

Dr. Charul Bhanji, *Technical Director*

Parvathi Chandran, *Manager Research Strategy & Communication*

Driti Ghosh, *Project Manager*



[www.regrow.in](http://www.regrow.in)



## Executive Summary

Hip replacements have become very common today. A prospective hip replacement patient is privy to a sea of information regarding orthopedic surgeons and surgery options before going under the knife. A lesser known fact, however, is why so many hips get replaced in the first place. The Indian Society of Hip and Knee Surgeons reported in 2019 that nearly 50% of all hip replacements are caused due to Avascular Necrosis.<sup>1</sup>

Avascular Necrosis (AVN) also called as osteonecrosis, is the slow death of bone tissue that occurs due to compromised blood supply. Tiny bone fractures lead to loss of biomechanical strength and compromises the structural and functional integrity of the joint. Gradual bone deterioration under continuous mechanical pressure ultimately collapses the joint. Today AVN is a prevalent disease in India but there is still a lack of understanding regarding current treatments for AVN and their efficacies.

This white paper is based on the findings from a survey designed for orthopedic doctors to determine demographics and etiology of AVN patients, treatment preferences and associated outcomes. It summarizes the survey results, discusses key findings and highlights the *need for a change of perception in the view of orthopedic doctors who treat patients suffering with AVN.*

### Disclaimer

The information included in this white paper is provided for information purposes only and it is not intended to constitute professional advice or replace consultation with a qualified medical practitioner. The information should not be treated as comprehensive and does not intend to provide diagnosis, treatment or any medical advice.

### Copyright Statement

All the contents herein are the property of Regrow Biosciences Private Limited and protected by the Indian Copyrights and other applicable laws. Any unauthorised copying, distribution or translation will constitute an infringement of copyright and other applicable laws. Regrow Biosciences Private limited trusts that this has been instructive and encourages the patient to consult with his or her orthopaedic physician or specialist regarding the OSSGROW® Bone Cell Therapy and its suitability. All cited trademarks are the property of their respective owners.

## Treatment Scenario

There is no standard-of-care available for the treatment of AVN globally.<sup>2</sup> However, several non-surgical and surgical remedies are being prescribed to AVN patients. *Bisphosphonates* such as alendronate or zoledronic acid are conservative measures used to manage the disease symptoms. It reduces the rate of bone resorption (osteoclast activity) which eventually prevents or delays the collapse of the hip joint.<sup>3</sup>

*Core decompression* is a widely practiced surgical treatment that aims to decompress the pressure built up in the bone by drilling. The restored blood supply releases the intraosseous pressure which manages the disease by stopping further bone degeneration.<sup>4</sup>

Various other conservative and surgical treatment options have been described in literature, but the procedures and outcomes are variable. It is also important to highlight that treatment outcomes differ with the grade of disease at the time of treatment.

It is alarming that for a disease that is so prevalent, there is no effective treatment that cures the patient. The ideal treatment goal for AVN is to provide pain relief in the affected joint, cease disease progression, prevent joint collapse, preserve the joint and regain joint movement. To that end, it is necessary to understand the major causes of the disease, the failure of current treatments to cease disease progression and the need for new therapies.

## Who did we survey?

130 orthopedic doctors who treated AVN patients responded to the survey that could be accessed through an online link (via Survey-Monkey) from 19<sup>th</sup> August 2019 to 31<sup>st</sup> December 2019. Figure 1 shows that 44% of doctors practiced in corporate hospitals and 32% practiced in private clinics. Around 60% of doctors were in clinical practice for more than 10 years. Remaining 40% doctors had an average clinical practice of 5 years.

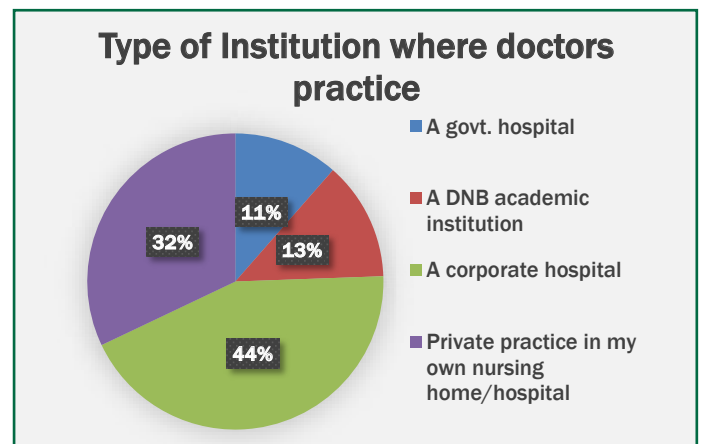


Figure 1 – Percentage of type of institution where the orthopedic doctors practiced

## What did we survey?

We collected information regarding

- Patient demographics
- Etiology of AVN
- Stages of disease and associated treatment options
- Expectations of current treatment outcomes

The information was collated, and results are summarized in this white paper. The paper covers the opinions of doctors on current treatments and their likelihood to accept and try newer treatments that are understood to be curative.

## Patient Demographics

- More than **80% doctors** treated patients with AVN in the **age group 20 to 40 years**. Majority of patients affected with AVN are in their youth and in the risk of being disabled. Literature on AVN patients also cite the affected age group of patients from 20 to 40 years.<sup>5</sup> Considering that a young patient will eventually suffer from a collapsed hip that will heavily impact his quality-of-life, it is imperative to preserve the affected hip using curative treatments.
- More than **90% responders** had treated **male patients** than female patients. Almost all patients suffered from AVN in the hip joint and only less than 1% patients had AVN in the shoulder joint.
- Patients with **bilateral AVN** were more than twice (**68.70%**) as much as patients with **unilateral AVN (31.30%)**. Quite often, the grades of AVN in both the hip joints are different at the time of diagnosis.
- Majority of doctors barely treated any patient in Grade I AVN. Most of the patients had Grade II, Grade III and Grade IV AVN at the time of diagnosis. Amongst them, patients in Grade II were the largest followed by near equal numbers in Grades in III and IV, respectively. It is evident that Grade I AVN is asymptomatic and patients are usually not aware of the disease at this stage. Symptoms start to appear from Stage II especially severe pain in the affected hip and groin that spreads to the knee.

## Symptoms and Diagnosis

Figure 2 shows response of doctors to most common symptoms seen in AVN patients. As seen in the Figure 2, 90% of doctors chose pain in the hip joint as the most common symptom seen in AVN patients followed by a limp while walking (62.60%). This was followed by limited range of motion (54.96%) and inability to sit cross-legged (48.09%).

Nearly **60% doctors diagnosed** patients using both **X-ray and MRI** and 25% doctors with only MRI. Less than 10% doctors used X-ray, MRI and CT-Scan and 7% doctors used only X-ray. MRI is the most preferred diagnostic tool due to high sensitivity and specific to detect lesions and hip pathology.<sup>6,7</sup>

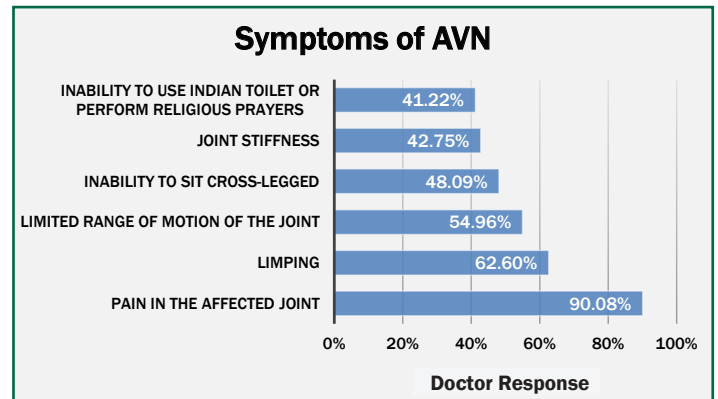


Figure 2 – Common symptoms seen in AVN patients reported by orthopedic doctors

## Etiology of AVN

Major causes of AVN from literature are alcohol abuse, steroid abuse, trauma. Many cases of idiopathic AVN have also been reported.

Figure 3 shows the doctor response to common causes of AVN in patients. In the Figure 3, 74% doctors reported that the number of patients due to trauma are less than 25%. **Majority of doctors reported highest number of patients (75% to 100%) were affected with idiopathic AVN.** Number of patients reported to be affected by AVN due to steroids was 5% more than those due to alcohol.

Amongst patients with a pre-existing illness that led to AVN, **sickle cell anemia** was the number one disease followed by diabetes and systemic lupus.

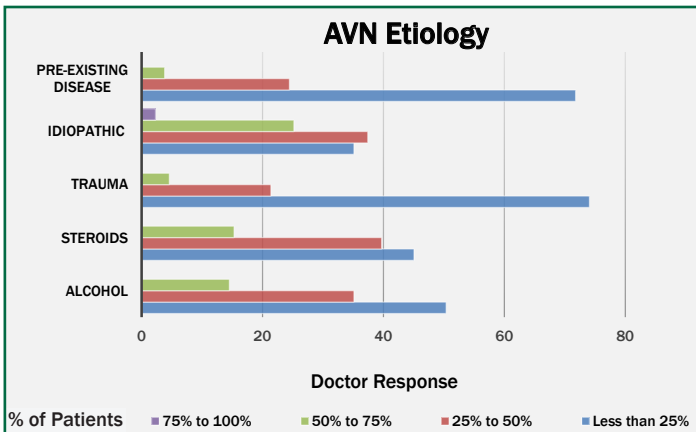


Figure 3 – Common causes of AVN in patients reported by orthopedic doctors

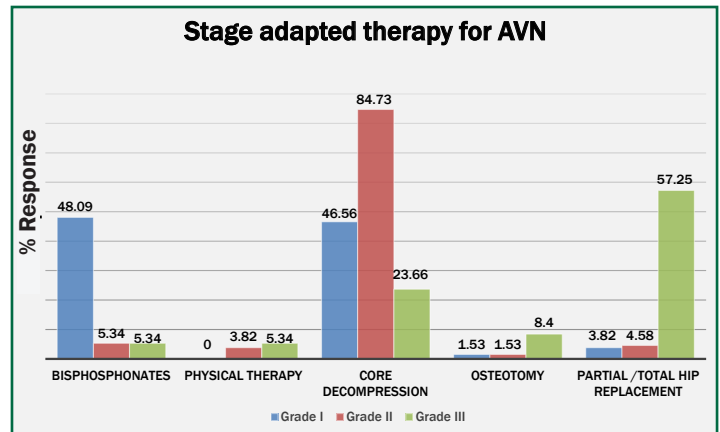


Figure 4 – Choice of treatment of doctors depending on the Grade of AVN

## Grade of AVN

Majority of doctors reported that barely one patient was treated in Grade I AVN. Amongst Grades II, III and IV AVN, nearly **90% of doctors treated patients in Grade II**. This was followed by patients in Grade III (89%) and then Grade IV (85%).

## Choice of treatment on the basis of Grade of AVN

Figure 4 shows the doctor response to the treatment of choice depending on the Grade of AVN at the time of diagnosis. As in the Figure 4, nearly 50% of doctors opted for administration of bisphosphonates for Grade I AVN followed by core decompression for Grade II AVN.

84.73% of doctors chose core decompression for Grade II pre-collapse stage AVN.

Nearly 60% doctors opted for partial or total hip replacement for a Grade III collapsed and flattened hip joint.

It can be seen that the most widely preferred and used treatment of choice by doctors is core decompression for early Grades I and II for AVN.

Majority of doctors (80%) performed between 10 to 20 core decompression surgeries every year. Nearly 40% of the doctors performed between 20 to 30 hip replacement surgeries per year.

## Current treatments and their outcomes

Figure 5 shows the percentage of doctor response to percentage success in core decompression. Nearly 60% doctors believe that core decompression -which is the most common choice of treatment used today- has a success of upto 50%.

Figure 6 shows doctor responses to different expectations from core decompression as a treatment for AVN. **Nearly 88% of the doctors believe that the clinical outcomes from core decompression are very unpredictable and does not benefit the patient in the long term.** Nearly 22.14% doctors expect core decompression to render no clinically significant benefits or a short-term outcome as a treatment for AVN.

Literature on core decompression clinical outcomes in patients with AVN also cite limited positive outcomes. Hopson et al. performed 21 core decompressions in 17 patients who had stage-I or II ischemic necrosis of the femoral head. After a mean length of follow-up of 39 months, healing was evident in only 8 hips (40 per cent). All twelve hips required additional surgical treatment; the average length of time before the additional treatment was required was 9.2 months. The study concluded that given the relatively poor long-term results and the considerable morbidity that was associated with core decompression, this treatment cannot be recommended <sup>8</sup>.



Koo et al. performed a randomized trial on 37 hips (33 patients) with early-stage avascular necrosis. 18 hips were randomly assigned to a core-decompression group and 19 to a conservatively treated group. At a minimum follow-up of 24 months, 14 of the 18 core decompressed hips (78%) and 15 of the 19 non-operated hips (79%) developed collapse of the femoral head. By survival analysis, there was no significant difference in the time to collapse between the two groups. The study concluded that core decompression is of no greater value than conservative management in preventing collapse in early osteonecrosis of the femoral head <sup>9</sup>.

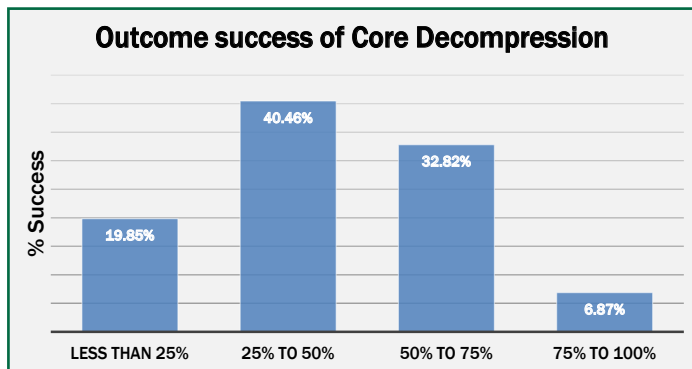


Figure 5 – Doctor responses to different treatment outcomes depending on the Grade of AVN

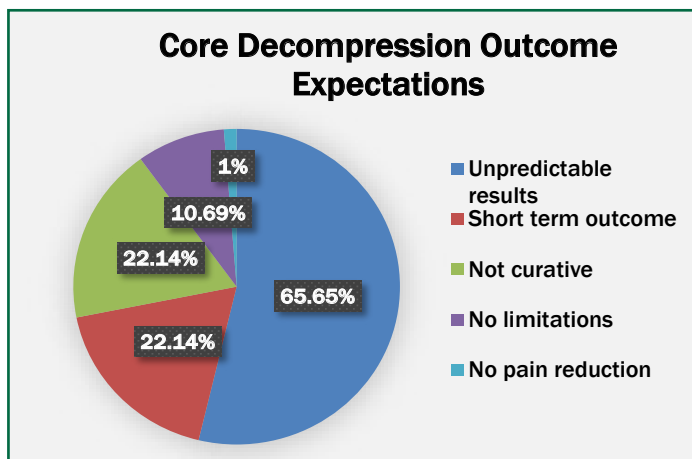


Figure 6 – Doctor responses to different outcomes of core decompression

## Opinion and expectations of new treatments for AVN

Figure 7 shows the doctor responses to accept newer treatments to cure AVN. **Nearly 80% doctors are very open and willing to try new biological treatments like autologous osteoblasts for the treatment of AVN.**

From Figure 8, more than 60% doctors expect newer treatments to give pain relief within 2 to 4 months, cease disease progression, delay the need for surgery or hip replacement for nearly 10 years.

OSSGROW<sup>®</sup> - adult live cultured autologous osteoblasts is a biological bone cell therapy that allows regeneration of new bone. The procedure is designed in a three-pronged manner to address the root cause of AVN and preserve the affected joint. The process involves restoring blood supply by core decompression, curettage of dead bone to allow space for new bone formation and implantation of autologous osteoblasts that regenerates new bone at the defect site.

Formation of new bone is key to restore the structural and biomechanical properties of the affected joint which prevents hip collapse and need for hip replacement. Preservation of the femoral head restores quality-of-life and the patient can resume daily physical activities

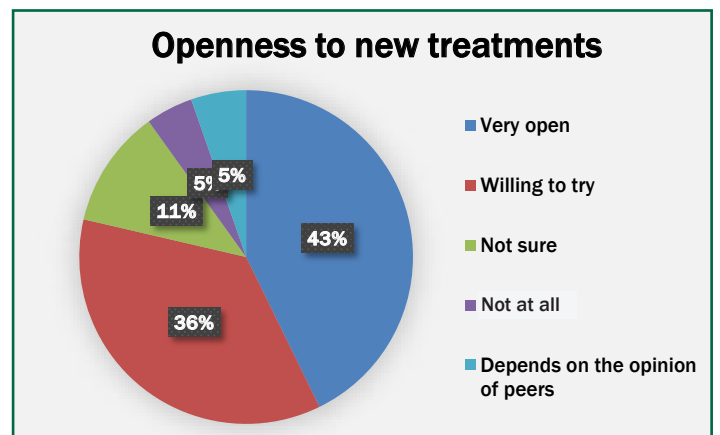


Figure 7 – Doctor responses to different outcomes of new treatments

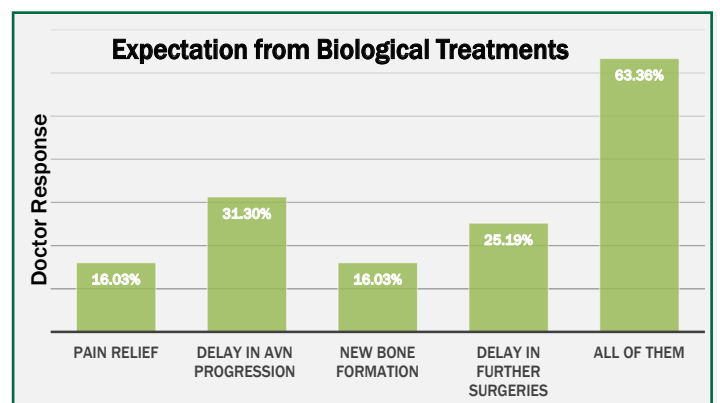


Figure 8 – Doctor responses to expectation of different outcomes from biological treatments

# Conclusion

AVN is a common disease affecting people in India, especially males. There exists no satisfactory treatment for AVN today as current remedies do not efficiently cure the patient. Core decompression has been the most widely used treatment according to the doctors who participated in this survey. Orthopedics treating AVN patients today do not expect satisfactory results from this treatment. Doctors expect newer treatments which are biological in nature to address the underlying disease pathology and offer better efficacies. Doctors are also willing to try newer treatments expected to have longer efficacy outcomes and that eventually eliminate the need of surgery for the patients suffering from AVN.

# Acknowledgment

We thank all the doctors who have spared their precious time from their busy schedules to have participated in this survey.

Name	Company	Location
Dr. A.K.Bera	Jeevan Deep Special Care and Diagnostic Centre	Behrampore
Dr. Abhishek Patil	Sahyadri Hospital	Pune
Dr. Aditya Agrawal	Dhiraj Hospital	Vadodra
Dr. Amarendra Nath Roy	Manmohini Hospital	Behrampore
Dr. Amit Kumar Agarwal	Apollo Hospital	New Delhi
Dr. Amit Mahajan	Mahajan Multispecialty Hospital	Pune
Dr. Amit Singh	Sankatmochan Orthopedic Centre	Gorakhpur
Dr. Amit Swamy	Swamy Hospital	Pune
Dr. Amitava Narayan Mukherjee	Mukherjee Orthopedic Clinic	Kolkata
Dr. Amol Patil	-	-
Dr. Anand	-	-
Dr. Anil Khadke	-	-
Dr. Anil Lokhande	Batra Hospital	New Delhi
Dr. Arnab Karmakar	IPGMER and SSKM Hospital	Kolkata
Dr. Arunangsu Bhattacharyya	Amri Hospital	Kolkata
Dr. Arvind Mehra	Paras Hospital	Gurgaon
Dr. Ashok Sachdeva	Supreme Hospital	Faridabad
Dr. Atul Sonawane	Jehangir Hospital	Pune
Dr. Atul Wankhede	Advanced Multispeciality Hospital	Mumbai
Dr. B L Prakash	Vanditha Orthopedic Centre	Bangalore
Dr. B.Chana Sekhar	Sunshine Hospital	Hyderabad
Dr. Banti C Dharmae	Dharma Hospital	Pune
Dr. Bhanu Prakash Reddy	Apollo Hospital,Jubilee Hills	Hyderabad
Dr. C D Mahajan	Mahajan Accident Hospital	Nandurbar
Dr. Chirag Jyotirvadan Dalai	Madhu Polyclinic and Nursing Home	Mumbai
Dr. Deepak	Rajiv Gandhi Cancer Institute	New Delhi
Dr. G V Reddy	-	-
Dr. Guddu Babladi	Babladi Clinic	Solapur
Dr. H M Prasanna	Pristine Hospital And Research Centre	Bangalore
Dr. Haripada Giri	IPGMER and SSKM Hospital	Kolkata
Dr. Harish Chandran	-	-
Dr. Harshraj Deshmukh	Apollo Clinic	Pune
Dr. Hashim Rashid	Fortis Hospital	-
Dr. Jacob Varghese	Lakeshore Hospital	Kochi
Dr. Jyoti Prakash	-	-
Dr. Kiran Kharat	Ruby Hall Clinic	Pune
Dr. Kirthi Paladugu	Srikara Hospitals Miyapur	Hyderabad
Dr. KJ Reddy	Apollo Hospital, Jubilee Hills	Hyderabad
Dr. Kn Subramanian	Vellamal Medical College	Madurai
Dr. Krishan Kumra	-	-
Dr. Kunal Bansal	Bansal Bone & Joint Institute	Pune
Dr. M.Srinivasa Reddy	-	-
Dr. Madhur Mahna	Centre For Joints, Spine and Childrens Orthopedics	New Delhi
Dr. Manne Bhavyachand	-	-
Dr. Mayur Kasat	Orthocare and Joint Replacement Clinic	Pune
Dr. Mayur Rabhadiya	-	-
Dr. Mithun N Oswal	Sagar Hospitals	Bangalore
Dr. N Anil Kumar	-	-
Dr. N Reddy	Apollo Hospital, Jubilee Hills	Hyderabad
Dr. Nantu Saha	-	-
Dr. Narendar Dasaraju	Apollo Hospital, Greems Road	Chennai
Dr. Natesh	Virinchi Hospital	Hyderabad
Dr. Navaladi Shankar	Apollo Hospital	Chennai
Dr. Navin K Shukla	ESI Hospital	Kolkata
Dr. Nazir Hasan	Burdwan Medical College	Kolkata
Dr. Nihit Jain	-	-
Dr. Nikhil Jadhav	Orthopedic And Fracture Clinic	Pune
Dr. Nikhul Tonge	-	-
Dr. Nilesh Shah	Sangini Clinic	Ahmedabad

Name	Company	Location
Dr. Nilesh Shete	-	-
Dr. Ninad Doshi	Madhekar hospital	Barshi
Dr. Nirmal Jangid	Jehangir Hospital	Pune
Dr. Nirmal Kumar Dey	JIMSH	Kolkata
Dr. Nitin Hiray	-	-
Dr. P R Damodaran	Apollo Hospital	Chennai
Dr. Pavan Jadhav	Panacea Hospital	Aurangabad
Dr. Prabhat Reddy Lakkireddi	Apollo Hospital, Jubilee hills	Hyderabad
Dr. Pradeep Pilajirao Kulkarni	-	-
Dr. Prasanna Nande	Nande Hospital	Pune
Dr. Rabinanath Saren	Cooch Behar Mission Hospital	Kolkata
Dr. Rahul Khanna	-	-
Dr. Rahul Kumar	Paras Hospital	Gurgaon
Dr. Rahul Rane	Dr L H Hiranandani Hospital	Powai
Dr. Rajasekhar	Mint Hospital	Chennai
Dr. Rajeev Joshi	Sancheti Hospital	Pune
Dr. Rajiv Gupta	Arthroscopy and Sports Injury Centre	Jaipur
Dr. Rajiv Kaul	MH Khadki	Pune
Dr. Rajkumar s Amaravati	St Johns Medical College and Hospital	Bangalore
Dr. Ravikumar	-	-
Dr. Rohan Bansal	Kingsway Hospital	Nagpur
Dr. Rohit Damor	Sports and Arthroscopy Centre	Ahmedabad
Dr. Ronen Roy	Fortis Hospital	Kolkata
Dr. Senthil Kamalasekaran	Fortis Hospital	Mumbai
Dr. Sai Laxman Anne	KIMS Hospital	Hyderabad
Dr. Sajil hamid	Bharti Hospital	Pune
Dr. Santosh	-	-
Dr. Santosh Bandu Kadam	Ashirwad Hospital	Beed
Dr. Sattyajeet Naik	Naik Hospital	Pune
Dr. Senthil Kamalasekaran	Chennai Ortho Clinic/Apollo Hospitals	Chennai
Dr. Shailesh Shewale	-	-
Dr. Shashank Kanchan	IQ City medical college	Durgapur
D. Shivdarshan Mohanlal Agarwal	Lotus Multipesiality Hospital	Pune
Dr. Siddharth Shah	Healing Bones Clinic	Pune
Dr. Smarajit Patnaik	Apollo Hospital	Bhubaneswar
Dr. Smruti Ranjan Panda	Mercy Hospital	Kolkata
Dr. Sourabh Shirguppe	-	-
Dr. Sourav Das	Medica Hospital	Kolkata
Dr. Sringeri	Polaris Hospital	Gurgaon
Dr. Srinivas Thati	Medics Healthcare	Hyderabad
Dr. Suday Mukherjee	AMRI Hospital	Kolkata
Dr. Sudhir Shivaji Lamkhade	Wellness Ortho & Surgical Centre	Pune
Dr. Sujit Kumar Tripathy	AIIMS Hospital	Bhubaneswar
Dr. Sujoy Kundu	Woodlands Hospital	Kolkata
Dr. Sushanth Somayaji	-	-
Dr. Sutanu Hazra	Medica Hospital	Kolkata
Dr. Syed Shamim	-	-
Dr. Tanmoy Karmakar	AMRI Hospital	Kolkata
Dr. Tarun Solanki	Chirayyu Orthopedic & Maternity Clinic	Kashipur
Dr. Tridib Kumar Sett	NRS Hospital	Kolkata
Dr. Udayan Das	KIMS Hospital	Bhubaneswar
Dr. Umesh Ghatyidak	HOSMAT Hospital	Bangalore
Dr. Unmesh Mahajan	Mahajan Ortho and Surgical Hospital	Nagpur
Dr. V S N Raju	ARC Orthopedic Hospital	Hyderabad
Dr. Vamshi Kiran Badam	Sunshine Hospital	Hyderabad
Dr. Varun Chandra	Charnock Hospital	Kolkata
Dr. Venkatesh	-	-
Dr. Vijay Kakatkar	Kakatkar Hospital	Nashik
Dr. Vivek patil	V Care orthopedic Centre	Hubli
Dr. Vivekananda Reddy	Apollo Hospitals	Nellore



## References

1. <http://www.ishks.com/pdf/ISHKS-registry-2019.pdf>
2. Agarwala S, Vijayvargiya M. Bisphosphonate combination therapy for non-femoral avascular necrosis. *J Orthop Surg Res.* 2019;14(1):112.
3. Drake MT, Clarke BL, Khosla S. Bisphosphonates: mechanism of action and role in clinical practice. *Mayo Clin Proc.* 2008;83(9):1032–1045. doi:10.4065/83.9.1032
4. Tripathy SK, Goyal T, Sen RK. Management of femoral head osteonecrosis: Current concepts. *Indian J Orthop.* 2015;49(1):28–45. doi:10.4103/0019-5413.143911
5. Moya-Angeler J, Gianakos AL, Villa JC, Ni A, Lane JM. Current concepts on osteonecrosis of the femoral head. *World J Orthop.* 2015;6(8):590–601. Published 2015 Sep 18. doi:10.5312/wjo.v6.i8.590
6. Stoica Z, Dumitrescu D, Popescu M, Gheonea I, Gabor M, Bogdan N. Imaging of avascular necrosis of femoral head: familiar methods and newer trends. *Curr Health Sci J.* 2009;35(1):23–28.
7. Zhang YZ, Cao XY, Li XC, et al. Accuracy of MRI diagnosis of early osteonecrosis of the femoral head: a meta-analysis and systematic review. *J Orthop Surg Res.* 2018;13(1):167.
8. Hopson CN, Siverhus SW. Ischemic necrosis of the femoral head. Treatment by core decompression. *The Journal of bone and joint surgery. American volume.* 1988 Aug;70(7):1048-51.
9. Koo KH, Kim R, Ko GH, Song HR, Jeong ST, Cho SH. Preventing collapse in early osteonecrosis of the femoral head. A randomised clinical trial of core decompression. *The Journal of bone and joint surgery. British volume.* 1995 Nov;77(6):870-4.



[www.regrow.in](http://www.regrow.in)

Copyright© 2020, Regrow Biosciences Pvt. Ltd.