

Osteochondral Lesions of the Talar Dome

Dinshaw Pardiwala¹, Sanjay Soni¹, Nandan Rao¹, Pradeep Mandapalli¹

Abstract

Osteochondral lesions of the talar dome (OLT) are common, with up to 50% of acute ankle sprains and fractures developing some form of articular cartilage injury. Although the optimal treatment of OLT has remained controversial, in general, a non-displaced lesion with intact articular cartilage should be treated non-operatively with immobilization and restriction of activity. Surgical treatment is indicated for separated or displaced lesions, or If conservative treatment fails to relieve pain in undisplaced lesions. Surgical treatment aims to restore the articular surface with a repair tissue similar to native cartilage and to provide long-term symptomatic relief. If the size of the lesion is not larger than 15 mm, or deeper than 7 mm, bone marrow stimulation technique (BMS) including excision of loose osteochondral fragments, curettage of the crater, and drilling or microfracture can be performed via an anterior or posterior arthroscopic approach. Although BMS has been proven to be an effective treatment for symptomatic patients with small osteochondral lesions of the talus, the reparative tissue formed is fibrocartilage with less durability compared to normal hyaline cartilage. Evidence suggests that large and deep lesions (>15mm diameter, >7 mm depth), or failed previous BMS techniques, should be treated with a replacement strategy such as autologous chondrocyte implantation or osteochondral autograft transfer. Autologous chondrocyte implantation techniques require a two-stage procedure, the first for chondrocyte harvest and the second for implantation after in-vitro culture expansion. Theoretically, the transplantation of chondrocyte-like cells into the defect will result in hyaline-like repair tissue. Osteochondral autograft transfer replaces the defect with a cylinder of viable hyaline cartilage and bone from a donor site in the ipsilateral knee. The need for a malleolar osteotomy and difficulty in gaining perpendicular access to the talar dome is the major limitation of this technique.

Introduction

Osteochondral lesion of the talus (OLT) is a common condition and may range from a small defect in the talar dome articular cartilage, to subchondral cysts, or osteochondral fragments. These lesions have been described by a variety of names, including osteochondritis dissecans, transchondral dome fracture, and osteochondral fracture. The etiology and pathogenesis of osteochondral injuries has been attributed to a variety of factors [1,2]. While most OLTs can be attributed to a traumatic event, lesions of nontraumatic origin may also occur in up to 24% of cases [3,4].

Trauma remains the leading cause of OLT

and this includes not only acute trauma as in a sprain or intra-articular fracture, but also repetitive microtrauma. A 4% radiographic incidence of OLT has been reported in a series of persistently symptomatic ankle sprains [5]. Additionally several studies have noted the incidence of bilateral OLT to be around 10% [6-8].

When OCDT occurs in a skeletally immature patient, it has been defined as juvenile osteochondritis dissecans of the talus (JOCDT) [9]. JOCDT is a rare pathology whose peculiarities are a subchondral bone alteration and a partially or completely detached osteochondral fragment. It's prevalence is difficult to be estimated, because of the large numbers of

misdiagnosed and asymptomatic cases (at least 38.4% are incidental diagnosis) [9,10]. The proposed etiology involved in the development of an osteochondritis dissecans are trauma, vascular, genetic, and endogenous [11]. Presently, the most widely accepted theory encompasses a vascular etiology and a concomitant overuse traumatic insult. It is hypothesized that subchondral bone sufferance following an initial damage, either vascular and traumatic in origin, is the main cause of chondral apoptosis and subsequent cartilage degeneration, eventually producing an osteochondral fragment.

The incidence of medial OLT is higher than that of lateral lesions. Canale reported that all lateral lesions have a history of trauma, while only 64% of medial lesions report trauma [12]. Medial lesions are usually non-displaced, cup-shaped, deeper, and more likely to change into cystic lesions, while lateral lesions, are shallow, wafer-shaped, and more likely to have a displaced fragment from its crater. Historically, lesion position was considered to be anterolateral or posteromedial. However, an analysis of

¹Arthroscopy & Sports Orthopaedics Service, Kokilaben Dhirubhai Ambani Hospital, Mumbai, India.

Address of Correspondence:

Dr. Dinshaw Pardiwala

Arthroscopy & Sports Orthopaedics Service, Kokilaben Dhirubhai Ambani Hospital, Mumbai, India.

Email: Dinshaw.Pardiwala@relianceada.com



Dr. Dinshaw Pardiwala



Dr. Nandan Rao

© 2018 Pardiwala et al | Asian Journal of Arthroscopy | Available on www.asianarthroscopy.com | doi:10.13107/aja.2456-1169.229

This is an Open Access article distributed under the terms of the Creative Commons Attribution Non-Commercial License (<http://creativecommons.org/licenses/by-nc/3.0>) which permits unrestricted non-commercial use, distribution, and reproduction in any medium, provided the original work is properly cited.

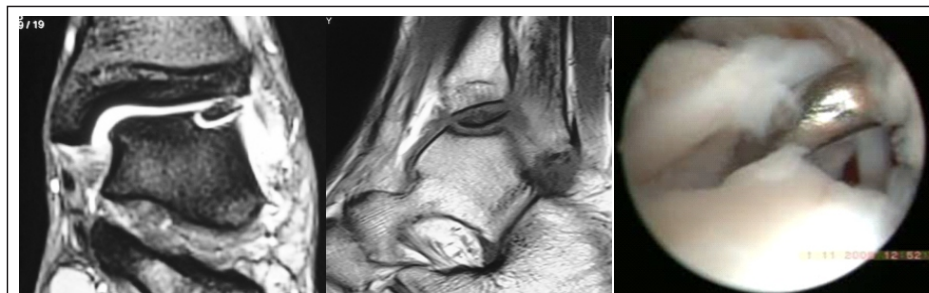


Figure 1: Berndt and Harty stage IV lateral talar OLT. (a) and (b) MRI reveals that the osteochondral fragment is completely avulsed and flipped. This is a contraindication for a trial of non-operative treatment. (c) Arthroscopy confirms that the chondral surface of the fragment is inferior, and the bony aspect is articulating with the tibial articular cartilage.

428 ankle MRIs with known OLTs revealed 53% of lesions medial and middle, and 26% lateral and middle. The vast majority of lesions were the in the middle (80%), with relatively fewer anterior or posterior lesions (6% and 14%, respectively) [13]. The prognostic significance of lesion location remains a topic of debate [14], with some authors reporting better outcomes in patients with medial lesions compared with those with lateral lesions.

Clinico-radiological Diagnosis

Olts are most commonly seen in young adult males (70%). Most physical signs and symptoms are similar to those seen in a variety of other ankle problems, therefore the diagnosis must be confirmed by imaging. The presenting complaints include pain, swelling, stiffness of the ankle, and in some cases mechanical symptoms of locking and catching. Symptoms are often exacerbated by prolonged weight bearing. Most patients relate the pain to a single injury, or recurrent sprains. On physical examination, there is often tenderness, decreased range of motion, pain with inversion or dorsiflexion, or an ankle effusion. The lack of these signs on physical exam do not exclude an OLT and often the physical examination signs may be subtle or absent. Additionally, physical signs and symptoms may differ depending on the location of the lesion.

Radiographs are the first imaging study performed. Oblique and plantar flexion views that avoid tibial overlap generally show an OLT more clearly than standard projections. Plantar-flexed mortise views are better able to visualize posteromedial lesions and dorsiflexed radiographs are better able to visualize anteromedial or anterolateral lesions [2]. However, plain radiographs may miss up to 50% of the injuries because of an inability

to assess the state of cartilage [4].

Magnetic resonance imaging can detect bone edema and other soft tissue injuries and has the capacity to distinguish between normal, native cartilage, repair cartilage (including fibrocartilage), and synovial tissue. While MRI has become the gold standard of imaging for OLT, it may exaggerate the severity of injury, either through signal patterns in the talus or due to associated marrow edema. Since lesion size has been established as a predictor of outcome and may be useful in directing treatment (lesions greater than 15 mm in diameter have shown a failure rate of 97% after arthroscopic bone marrow stimulation [15]) great care must be taken when measuring lesion size on MRI so that size is not over estimated. T2 cartilage mapping MRI offers greater sensitivity to cartilage change, and facilitates clarification of the depth of cartilage damage. Several studies have established the effectiveness of T2 mapping in quantitatively evaluating collagen fibre architecture of the repair cartilage [16].

While CT scans can be used in preoperative planning to visualize the location of the lesion, determine the necessity of malleolar osteotomy, and delineate subchondral cysts and bone loss, they are unable to assess cartilage as effectively as MRI. The addition of single photon emission computerized tomography (SPECT) imaging to CT adds to the diagnostic value of

CT scanning by identifying co-existing pathology as well as showing the activity around the lesion of interest [17]. While MRI remains the imaging method of choice for most, CT and SPECT-CT imaging can better delineate the osseous anatomy and help determine the activity and extent of the lesion.

Staging

The original radiographic classification system for OLT was developed by Berndt and Harty in 1959 [6] and is still the most commonly used staging system (Table 1). Multiple additional classification systems have been proposed based on MRI. Mintz et al. showed an 83% correlation in staging classified by MRI integrity of the overlying cartilage and findings at the time of arthroscopy (Table 2). When patients were grouped into disease negative (Stage 0-I) or disease positive (Stage II-V), the authors noted a sensitivity of 95% and specificity of 100% [26].

Treatment

The natural history of OLT remains unclear due to a paucity of longitudinal follow-up studies. Various non-operative and operative treatment strategies have been described for OLT including excision, excision with bone marrow stimulation, excision with particulated juvenile cartilage grafting, retrograde drilling, autogenous chondrocyte implantation, osteochondral autograft transplantation, and osteochondral allograft transplantation [19-21]. There is no firm evidence in current literature that any one technique is superior [22-24].

Several studies have suggested patient factors

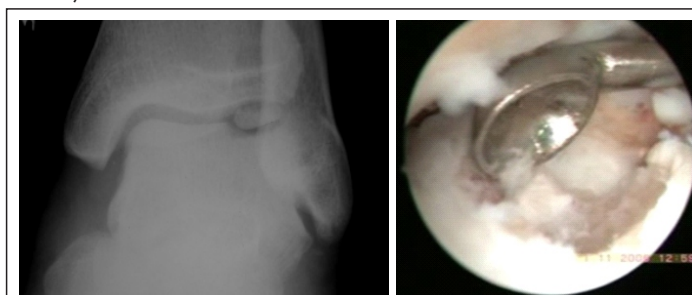

Figure 2: Arthroscopic bone-marrow stimulation is the most commonly utilized primary treatment strategy for symptomatic osteochondral lesions of the talus that are less than 15 mm in diameter. (a) AP radiograph of lateral OLT grade IV of 10 mm diameter. (b) Bone marrow stimulation involves excision of the loose, avascular fragment, curettage of the defect site such that healthy bone is exposed and a stable margin of healthy cartilage is achieved, followed by microfracture.

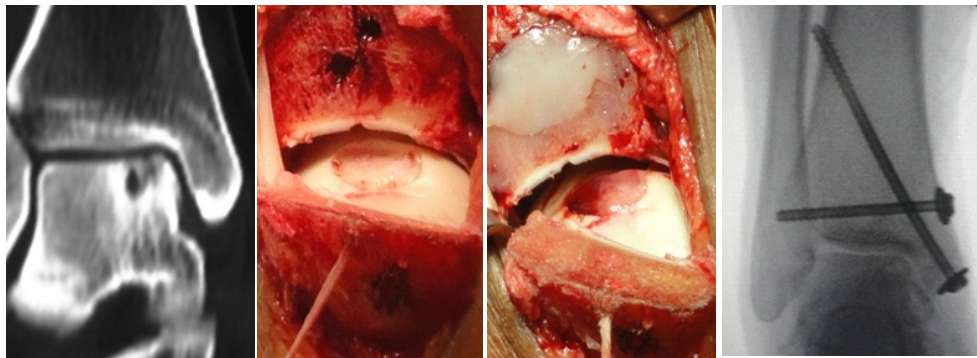


Figure 3: OLT larger than 15 mm or deeper than 7 mm are indicated for autologous chondrocyte implantation (ACI). ACI involves the transplantation of cultured chondrocytes into the defect, thereby facilitating a hyaline-rich repair. (a) CT scan of a stage III medial talar osteochondral lesion with cystic degeneration and a lesion depth of 10 mm. (b) Posteromedial talar lesions warrant an open approach with malleolar osteotomy for adequate exposure during implantation. (c) The fibrin ACI sets within 5 minutes of delivery. (d) Fixation of the pre-drilled malleolar osteotomy.

and lesion characteristics that prognosticate the operative treatment of OLT. Lesions smaller than 15 mm [15, 25-27], contained lesions [28], and anterolateral lesions [28] are considered to be the positive prognostic indicators. Negative prognostic factors include older age (> 33-40 years old) [25, 29], lesions deeper than 7 mm [14, 29], lesions larger than 15 mm [25], cystic lesions [14], medial talar lesions [29], higher BMI, history of trauma, longer duration of symptoms, and presence of osteophytes [15].

NON-OPERATIVE TREATMENT

The treatment of OCLs is dictated by size and location of the lesion as well as the activity level of the patient. Asymptomatic OCLs of the talus, or mildly symptomatic lesions in pediatric populations may resolve without treatment, in which case there is variable need for immobilization or protective weight bearing [2]. Spontaneous healing in adult populations, on the other hand, is uncommon [30].

The indications for non-operative treatment include asymptomatic OLT, and patients who have symptomatic non-displaced OLT lesions (Berndt and Harty grade I and grade II). Patients with intact cartilage as determined by MRI can also be treated non-

operatively. In paediatric patients with open tibial physes, even symptomatic small lesions of grade III may be given a non-operative trial of treatment. The accepted contraindication of non-operative treatment is a displaced intra-articular osteochondral fragment [31][Fig.1].

Conservative management usually consists of rest/restriction of activities, non-weight bearing with immobilization in a short leg cast for 3 weeks to 4 months, followed by progressive weight bearing in a brace, with physical therapy for 6-10 weeks [32]. The purpose of conservative treatment is to decrease loading of the injured cartilage, resolve bone oedema, and prevent bone necrosis with collapse. Another objective is to allow the detached fragment to heal to the underlying and surrounding bone [33]. A short course of bisphosphonates may also help prevent bone necrosis. However, there is no consensus in literature regarding the duration of nonoperative treatment, method of immobilization, weight bearing status, the use of NSAIDs, and physical therapy protocol.

The functional outcomes after conservative treatment of OLT have been described in the

literature with variable methods and results. In a review of 14 studies, conservative treatment of Berndt and Hardy type I, II, and medial type III lesions was effective in alleviating clinical symptoms in 59% of patients when treated with rest and activity restriction. Treatment was effective for 41% in patients immobilized in a plaster cast, and combined success rate of the 2 groups was 45% [34].

Klammer reported no increase in symptoms in 86% (43/48 ankles) of minimally symptomatic OLTs treated nonoperatively, followed at least two years with MRI [35]. On the other hand, nonoperative treatment provided good to excellent results in as few as 54% of patients with cystic OLTs [30]. In addition, few studies reported that arthritis of the ankle joint has been observed in approximately 50 percent of the patients who were treated with conservative treatment, but it could not be determined whether operative intervention might prevent the degeneration of the ankle joint [12]. McCullough studied a small case series of 10 patients with an average follow-up of 15 years and 11 months and found that OCD lesions may not heal over many years, but the ankle joints were relatively asymptomatic and arthrosis was minimal [36]. In addition, no radiographic difference of arthritis was noted between the patients who underwent conservative versus operative procedure for OLT treatment.

Surgical Treatment

The aims of operative treatment are to obtain pain relief and restore ankle joint function by removal of the unstable chondral or osteochondral fragment, debridement of the OLT crater, stabilization of the surrounding articular cartilage rim and subchondral bone, and stimulate bone and cartilage healing. Arthroscopic bone marrow stimulation (BMS) is recommended for OLTs which are less than 15 mm in maximum surface

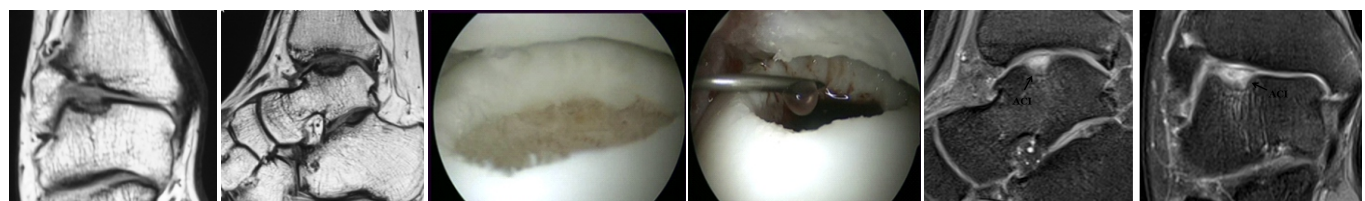
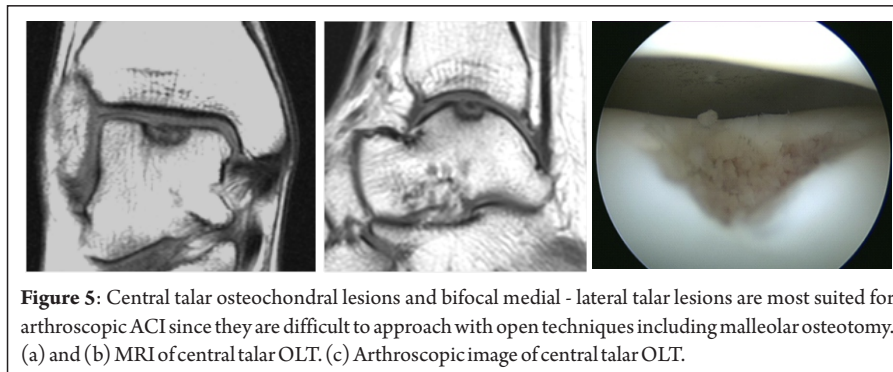


Figure 4: Well contained OLT are ideally suited for arthroscopic ACI. (a) and (b) MRI of lateral OLT reveals a well-contained grade IV lesion. (c) Arthroscopic OLT excision with stable margin preparation. (d) Fibrin ACI implantation performed with air arthroscopy. (e) and (f) Post operative MRI reveals complete homogenous graft fill with a continuous and well-defined lamina splendens.



diameter and no deeper than 7 mm [15, 25]. On the other hand, large or deep lesions, and lesions that have failed primary bone marrow stimulation surgery should be considered for autologous chondrocyte implantation (ACI), or osteochondral autograft transplantation [21, 37].

The indications for operative treatment include failure of conservative treatment for a period of 6 weeks to 6 months [15], and Berndt and Harty grade III and IV lesions [12, 38]. There is no current consensus on the definitive timing for operative treatment. O' Farrell recommended that the best timing of surgery is within 12 months after an inciting injury [39]; however, Alexander demonstrated that delaying surgery several months (range, 3 to 36 months) did not affect the outcomes of operative treatment [40]. Postoperative protocols vary based on the specific treatment methods but generally involve early range of motion, protected weight-bearing in a brace, and delayed return to sports.

Arthroscopic Bone Marrow Stimulation (BMS)

Arthroscopic bone-marrow stimulation involving drilling or microfracture is the most commonly utilized primary treatment strategy for symptomatic osteochondral lesions of the talus that are less than 15 mm in diameter [15,33,41]. This treatment is low-cost, technically easy, and minimally invasive, with low complication rates and minimal postoperative pain. Bone marrow stimulation should be accompanied by excision and curettage of the defect site, such that the calcified layer is removed and a stable margin of healthy cartilage is achieved [Fig.2]. The primary objective of bone-marrow stimulation is to breach the subchondral plate at 5 mm intervals, thereby allowing pluripotent mesenchymal stem cells to accumulate into the base of the defect site

from the underlying bone marrow. Intraoperatively, the release of fat droplets from the bone puncture confirms that adequate depth of awl penetration has been achieved. The subsequent formation of a fibrin clot initiates an inflammatory response, during which the release of cytokines and growth factors stimulates tissue healing. Mesenchymal stem cells begin to differentiate into chondrocyte-like cells that ultimately form a repair tissue expressing mainly type-II collagen in a proteoglycan matrix at six to eight weeks after injury. However, the ensuing surface fibrillation, proteoglycan depletion, and chondrocyte death result in a biological shift to fibrocartilaginous repair tissue exhibiting primarily type-I collagen at one year [42]. Type-I collagen retains inherently different biological and mechanical properties compared with hyaline cartilage, and it may degenerate over time.

A systematic review by Zengerink concluded that excision, curettage, and bone-marrow stimulation represented the treatment strategy of choice for primary osteochondral lesions of the talus, with an 85% success rate in a total of 386 patients [33]. Smaller lesions have a more successful clinical outcome. Chuckpaiwong performed an analysis of 105 patients followed prospectively for a mean of 31.6 months and reported no treatment

failures in lesions with a size of <15 mm, irrespective of lesion location [15]. Conversely, there was only one successful outcome in thirty-two patients with a lesion size of >15 mm. Cuttica assessed edema on follow-up MRI studies after microfracture in twenty-nine patients with thirty osteochondral lesions of the talus [43]. At a mean of 81.5 weeks after surgery, sixteen ankles (53%) had a fair or poor outcome, with better results seen in patients with a lower grade of edema intensity. Lee reported a case series using second-look arthroscopy, which was performed on twenty ankles one year after microfracture. Despite good to excellent AOFAS scores for 90% of the ankles, the repair tissue in eight ankles (40%) was graded as abnormal (grade III) according to the International Cartilage Repair Society system, while seven ankles (35%) demonstrated incomplete healing (stage D) according to the Ferrel and Cheng classification system [44]. Ferrel retrospectively evaluated fifty patients, including forty-four who had drilling and six who had an abrasion arthroplasty, with a mean follow-up of seventy-one month [45]. Thirty-four percent of the patients demonstrated advancement by at least one grade of arthritis on radiographs, and a subset of seventeen patients demonstrated a 35% decline in the modified Weber score over five years. Collectively, these data suggest deterioration of the fibrocartilage and declining outcome scores over time.

Autologous Chondrocyte Implantation

Autologous chondrocyte implantation involves the transplantation of viable, cultured chondrocytes into the defect, thereby facilitating a hyaline-rich repair tissue. Although earlier generations of ACI warranted an open approach with malleolar

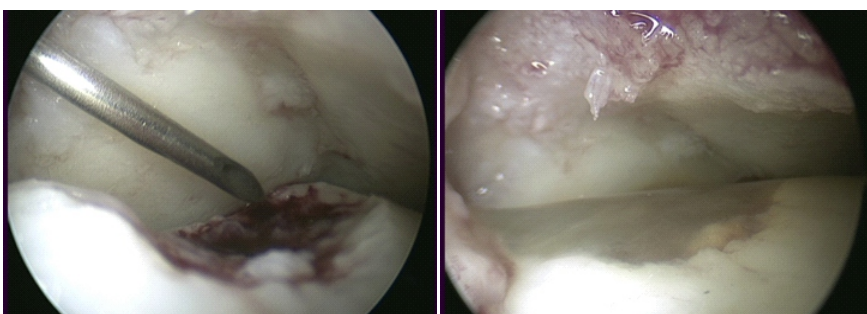


Figure 6: Arthroscopic ACI.

- (a) The step of cell implantation is performed as a dry arthroscopy.
 (b) The chondrocytes-fibrin mixture sets within 5 minutes of implantation.

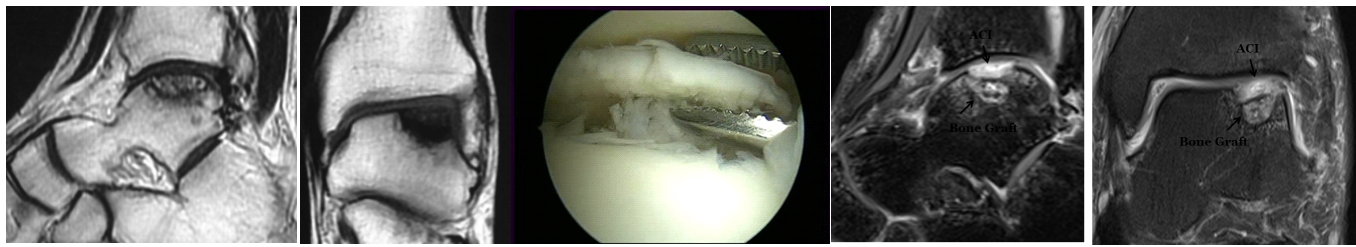


Figure 5: Central talar osteochondral lesions and bifocal medial - lateral talar lesions are most suited for arthroscopic ACI since they are difficult to approach with open techniques including malleolar osteotomy. (a) and (b) MRI of central talar OLT. (c) Arthroscopic image of central talar OLT.

osteotomy for implantation [Fig.3], the latest generation of fibrin ACI incorporates an injectable delivery system for the cultured chondrocytes-fibrin mixture, and is particularly suited to approach large anterior [Fig.4] and central talar OLT [Fig.5] via an arthroscopic approach. ACI involves a two-stage operation. Stage 1 involves arthroscopic debridement of the talar lesion with ipsilateral knee arthroscopic chondral biopsy. Stage 2 involves arthroscopic implantation of the cultured chondrocytes 4-6 weeks following stage 1. The step of cell implantation is performed as a dry arthroscopy. The chondrocytes-fibrin mixture sets within 7 minutes of implantation [Fig.6]. Larger lesions associated with extensive bone loss are treated with bone grafting along with ACI [Fig.7].

Giannini reported on forty-six patients who underwent matrix-induced autologous chondrocyte implantation in the talus for posttraumatic lesions [46]. The patients were followed prospectively for thirty-six months and demonstrated a significant improvement in the mean AOFAS score from 57.2 points preoperatively to 89.5 points postoperatively. The initial three patients in the series underwent second-look arthroscopy with tissue biopsy in which histological examination revealed repair tissue similar to hyaline cartilage. Magnan evaluated thirty patients with a mean lesion size of 2.36 cm² who were treated with matrix-induced autologous chondrocyte implantation [47]. The mean AOFAS score improved from 36.9 points preoperatively to 83.9 points at a mean follow-up of forty-five months (range, eighteen to ninety-six months). Only 50% of the patients

returned to their previous sporting activities. Quirbach evaluated MRI T2 cartilage maps in twelve patients after matrix induced autologous chondrocyte implantation, and reported a repair tissue that was no different from the tissue in a healthy control group [48].

Autologous Osteochondral Transplantation

Autologous osteochondral transplantation involves transplanting one or more cylindrical osteochondral grafts harvested from the ipsilateral knee to a defect site in the talus. Placing the donor grafts in the most congruent position possible to avoid surface incongruities on the talus is critical. It is indicated in patients with large cystic lesions or secondarily after failed index procedures. The advantages of this technique include replacing the defect with viable hyaline cartilage, without the need for a two-stage

procedure. The disadvantages are the need for graft harvest and the associated donor site morbidity, differences in surface curvature between the graft and host tissues, the poor potential for healing at the cartilage interface of the graft, and the need for a malleolar osteotomy.

Hangody reported on ninety-eight patients who underwent autologous osteochondral transplantation in the talus. 93% of the patients had good to excellent clinical results on the basis of evaluation with the Hannover Scoring System [49]. Long-term donor-site knee pain was present in 3%. Kennedy and Murawski also reported good functional results at a mean follow-up of 28.02 months postoperatively in seventy-two patients who underwent autologous osteochondral transplantation [50]. Three patients (4%) reported donor-site knee pain after the operation, and one patient required the

Table 1: Berndt and Harty radiographic classification of talar osteochondral lesions.

Stage	
I	Compression fracture with intact overlying cartilage
II	Incomplete avulsion of an osteochondral fragment
III	Complete avulsion of an osteochondral fragment without displacement
IV	Avulsed fragment displaced into joint

Table 2: MRI grading system for osteochondral lesions of the talus.

Stage	
0	Normal Cartilage
I	Abnormal cartilage signal but intact
II	Fibrillation or fissures in cartilage not extending to bone
III	Cartilage flap present or bone exposed
IV	Loose nondisplaced osteochondral fragment
V	Displaced osteochondral fragment

decompression of a cyst that had developed beneath the graft site two years after the operation.

Autologous osteochondral transplantation of the talus has the potential to provide good

clinical outcomes in the short to medium-term time periods, with results that do not appear to decrease over time. The procedure is technically demanding since perpendicular access to the talar dome despite a medial malleolar osteotomy is a challenge. Moreover,

implanting the donor grafts in a congruent position relative to the native cartilage is difficult. Although the osteotomy required to access the talar dome is not a cause for concern, donor-site knee pain is a complication in some series.

Conclusions & Keypoints

Osteochondral lesions of the talus are an increasingly diagnosed condition and are most commonly secondary to trauma. Current medical evidence suggests that smaller lesions can be effectively treated with bone marrow stimulation, however, larger and deeper lesions should be treated with either autologous chondrocyte implantation or osteochondral autograft transfer. The reported outcomes for each of these techniques, when used for the correct indications, are excellent

References

- Zengerink M, Struijs PA, Tol JL, van Dijk CN. Treatment of osteochondral lesions of the talus: a systematic review. *Knee Surg Sports Traumatol Arthrosc*. 2010;18:238-246.
- O'Loughlin PF, Heyworth BE, Kennedy JG. Current concepts in the diagnosis and treatment of osteochondral lesions of the ankle. *Am J Sports Med*. 2009;20:1-13.
- Roden S, Tillegard P, Unanderscharin L. Osteochondritis dissecans and similar lesions of the talus: report of fifty-five cases with special reference to etiology and treatment. *Acta Orthop Scand*. 1953;23:51-66.
- Dragoni M, Bonasia DE, Amendola A. Osteochondral talar allograft for large osteochondral defects: technique tip. *Foot Ankle Int*. 2011;32:910-917.
- Bosien WR, Staples OS, Russell SW. Residual disability following acute ankle sprains. *J Bone Joint Surg Am* 1955; 37-A(6): 1237-43.
- Berndt AL, Harty M. Transchondral fractures (osteochondritis dissecans) of the talus. *J Bone Joint Surg Am* 1959; 41-A: 988-1020.
- Blevins FT, Steadman JR, Rodrigo JJ, Silliman J. Treatment of articular cartilage defects in athletes: an analysis of functional outcome and lesion appearance. *Orthopedics* 1998; 21(7): 761-7.
- Hermanson E, Ferkel RD. Bilateral osteochondral lesions of the talus. *Foot Ankle Int* 2009; 30(8): 723-7.
- Perumal V, Wall E, Babekir N. Juvenile osteochondritis dissecans of the talus. *J Pediatr Orthop*. 2007;27:821-825.
- Kessler JI, Weiss JM, Nikizad H, et al. Osteochondritis dissecans of the ankle in children and adolescents: demographics and epidemiology. *Am J Sports Med*. 2014;42:2165-2167.
- Zwingmann J, Südkamp NP, Schmal H, Niemeier P. Surgical treatment of osteochondritis dissecans of the talus: a systematic review. *Arch Orthop Trauma Surg*. 2012;132:1241-1250.
- Canale ST, Belding RH. Osteochondral lesions of the talus. *J Bone Joint Surg Am* 1980; 62(1): 97-102.
- Elias I, Zoga AC, Morrison WB, Besser MP, Schweitzer ME, Raikin SM. Osteochondral lesions of the talus: localization and morphologic data from 424 patients using a novel anatomical grid scheme. *Foot Ankle Int* 2007; 28(2): 154-61.
- Choi WJ, Choi GW, Kim JS, Lee JW. Prognostic significance of the containment and location of osteochondral lesions of the talus: independent adverse outcomes associated with uncontained lesions of the talar shoulder. *Am J Sports Med*. 2013;41:126-133.
- Chuckpaiwong B, Berkson EM, Theodore GH. Microfracture for osteochondral lesions of the ankle: outcome analysis and outcome predictors of 105 cases. *Arthroscopy*. 2008;24:106-112.
- Battaglia M, Rimondi E, Monti C, et al. Validity of T2 mapping in characterization of the regeneration tissue by bone marrow derived cell transplantation in osteochondral lesions of the ankle. *Eur J Radiol*. 2011;80:132-139.
- Meftah M, Katchis SD, Scharf SC, Mintz DN, Klein DA, Weiner LS. SPECT/CT in the management of osteochondral lesions of the talus. *Foot Ankle Int* 2011; 32(3): 233-8.
- Mintz DN, Tashjian GS, Connell DA, Deland JT, O'Malley M, Potter HG. Osteochondral lesions of the talus: a new magnetic resonance grading system with arthroscopic correlation. *Arthroscopy* 2003; 19(4): 353-9.
- Schachter AK, Chen AL, Reddy PD, Tejwani NC. Osteochondral lesions of the talus. *J Am Acad Orthop Surg* 2005; 13(3): 152-8.
- Verhagen RA, Struijs PA, Bossuyt PM, van Dijk CN. Systematic review of treatment strategies for osteochondral defects of the talar dome. *Foot and ankle clinics* 2003; 8(2): 233-42.
- Hannon CP, Smyth NA, Murawski CD, Savage-Elliott I, Deyer TW, Calder JD, et al. Osteochondral lesions of the talus: aspects of current management 2014.
- Murawski CD, Kennedy JG. Operative treatment of osteochondral lesions of the talus. *J Bone Joint Surg Am* 2013; 95(11): 1045-54.
- Zwingmann J, Südkamp NP, Schmal H, Niemeier P. Surgical treatment of osteochondritis dissecans of the talus: a systematic review. *Arch Orthop Trauma Surg* 2012; 132(9): 1241-50.
- Van Bergen CJ, Kox LS, Maas M, Siersevelt IN, Kerkhoffs GM, van Dijk CN. Arthroscopic treatment of osteochondral defects of the talus: outcomes at eight to twenty years of follow-up. *J Bone Joint Surg Am* 2013; 95(6): 519-25.
- Cuttica DJ, Smith WB, Hyer CF, Philbin TM, Berlet GC. Osteochondral lesions of the talus: predictors of clinical outcome. *Foot Ankle Int* 2011; 32(11): 1045-51.
- Deol PP, Cuttica DJ, Smith WB, Berlet GC. Osteochondral lesions of the talus: size, age, and predictors of outcomes. *Foot Ankle Clin* 2013;18(1): 13-34.
- Kumai T, Takakura Y, Higashiyama I, Tamai S. Arthroscopic drilling for the treatment of osteochondral lesions of the talus. *J Bone Joint Surg Am* 1999; 81(9): 1229-35.
- Choi WJ, Jo J, Lee JW. Osteochondral lesion of the talus: prognostic factors affecting the clinical outcome after arthroscopic marrow stimulation technique. *Foot Ankle Clin* 2013; 18(1): 67-78.
- Yoshimura I, Kanazawa K, Takeyama A, et al. Arthroscopic bone marrow stimulation techniques for osteochondral lesions of the talus: prognostic factors for small lesions. *Am J Sports Med* 2013; 41(3): 528-34.
- Shearer C, Loomer R, Clement D. Nonoperatively managed stage 5 osteochondral talar lesions. *Foot Ankle Int*.2002;23:651-654.
- Kristensen G, Lind T, Lavard P, Olsen PA. Fracture stage 4 of the

- lateral talar dome treated arthroscopically using Biofix for fixation. *Arthroscopy* 1990; 6(3): 242-4.
32. Badekas T, Takvorian M, Souras N. Treatment principles for osteochondral lesions in foot and ankle. *Int Orthop* 2013; 37(9): 1697-706.
 33. Zengerink M, Struijs PA, Tol JL, van Dijk CN. Treatment of osteochondral lesions of the talus: a systematic review. *Knee Surg Sports Traumatol Arthrosc* 2010; 18(2): 238-46.
 34. Tol JL, Struijs PA, Bossuyt PM, Verhagen RA, van Dijk CN. Treatment strategies in osteochondral defects of the talar dome: a systematic review. *Foot Ankle Int.* 2000;21:119-126.
 35. Klammer G, Maquieira GJ, Spahn S, Vigfusson V et al. Natural history of nonoperatively treated osteochondral lesions of the talus. *Foot Ankle Int.* 2015 Jan;36(1):24-31.
 36. McCullough CJ, Venugopal V. Osteochondritis dissecans of the talus: the natural history. *Clin Orthop Relat Res* 1979; (144): 264-8.
 37. McGahan PJ, Pinney SJ. Current concept review: osteochondral lesions of the talus. *Foot Ankle Int* 2010; 31(1): 90-101.
 38. Huylebroek JF, Martens M, Simon JP. Transchondral talar dome fracture. *Arch Orthop Trauma Surg* 1985; 104(4): 238-41.
 39. O'Farrell TA, Costello BG. Osteochondritis dissecans of the talus. The late results of surgical treatment. *J Bone Joint Surg Br* 1982; 64(4):494-7.
 40. Alexander AH, Lichtman DM. Surgical treatment of transchondral talar-dome fractures (osteochondritis dissecans). Long-term follow-up. *J Bone Joint Surg Am* 1980; 62(4): 646-52.
 41. Murawski CD, Foo LF, Kennedy JG. A review of arthroscopic bone marrow stimulation techniques of the talus: the good, the bad, and the causes for concern. *Cartilage.* 2010;1(2):137-44.
 42. Mitchell N, Shepard N. The resurfacing of adult rabbit articular cartilage by multiple perforations through the subchondral bone. *J Bone Joint Surg Am.*1976;58(2):230-3.
 43. Cuttica DJ, Shockley JA, Hyer CF, Berlet GC. Correlation of MRI edema and clinical outcomes following microfracture of osteochondral lesions of the talus. *Foot Ankle Spec.* 2011;4(5):274-9.
 44. Lee KB, Bai LB, Yoon TR, Jung ST, Seon JK. Second-look arthroscopic findings and clinical outcomes after microfracture for osteochondral lesions of the talus. *Am J Sports Med.* 2009;37(Suppl 1):63S-70S.
 45. Ferkel RD, Zanotti RM, Komenda GA, Sgaglione NA, Cheng MS, Applegate GR, Dopirak RM. Arthroscopic treatment of chronic osteochondral lesions of the talus: long-term results. *Am J Sports Med.* 2008;36(9):1750-62.
 46. Giannini S, Buda R, Vannini F, Di Caprio F, Grigolo B. Arthroscopic autologous chondrocyte implantation in osteochondral lesions of the talus: surgical technique and results. *Am J Sports Med.* 2008;36(5):873-80.
 47. Magnan B, Samaila E, Bondi M, Vecchini E, Micheloni GM, Bartolozzi P. Three dimensional matrix-induced autologous chondrocytes implantation for osteochondral lesions of the talus: midterm results. *Adv Orthop.* 2012;2012:942174. Epub 2012 Apr 17.
 48. Quirbach S, Trattng S, Marlovits S, Zimmermann V, Domayer S, Dorotka R, Mamisch TC, Bohndorf K, Welsch GH. Initial results of in vivo high-resolution morphological and biochemical cartilage imaging of patients after matrix-associated autologous chondrocyte transplantation (MACT) of the ankle. *Skeletal Radiol.*2009;38(8):751-60.
 49. Hangody L, V'as'arhelyi G, Hangody LR, S'uk'osd Z, Tibay G, Bartha L, Bod'o G. Autologous osteochondral grafting—technique and long-term results. *Injury.*2008;39(Suppl 1):S32-9.
 50. Kennedy JG, Murawski CD. The treatment of osteochondral lesions of the talus with autologous osteochondral transplantation and bone marrow aspirate concentrate: surgical technique. *Cartilage.* 2011;2:327-36.

Conflict of Interest: NIL
Source of Support: NIL

How to Cite this Article

Pardiwala D, Soni S, Rao N, Mandapalli P. Osteochondral Lesions of the Talar Dome. *Asian Journal Arthroscopy.* May-Aug 2018;3(2):13-19.